

## Intra-articular Injection of Autologous Fat Micro Graft in Sheep Hind Knee Joints

Sabah Moshref<sup>1</sup>, Yasir Jamal<sup>2</sup>, Laila A. Hummdi<sup>3</sup>, Abdullah M Kaki<sup>4</sup> and Amro Al-Hibshi<sup>5</sup>

<sup>1</sup>Department of Surgery, King Abdulaziz University (**Corresponding Author**), E-mail: dr. [sabahmoshref@gmail.com](mailto:sabahmoshref@gmail.com), P.O. Box: 80215, Postal Code: Jeddah 21589.

<sup>2</sup>Department of Surgery, King Abdulaziz University

<sup>3</sup>Department of Biology, Science Faculty for Girls - King Abdul-Aziz University- Jeddah- Saudi Arabia.

<sup>4</sup>Department of Anesthesia and Critical Care, King Abdulaziz University

<sup>5</sup>Department of Orthopedics, Faculty of Medicine, King Abdulaziz University.

[Lhamdi@kau.edu.sa](mailto:Lhamdi@kau.edu.sa)

**Abstract: Background:** The aim of this study is to evaluate the safety and effects of intra-articular injection of Autologous fat micro graft into normal animals hind knee joints. **Methods:** Six sheep were enrolled in the study. Under monitored anesthesia care, autologous fat micro graft was harvested from tail fat of the animal using tumescent technique. 7-10 ml of the separated fat was injected intra-articularly to the Rt hind knee joint of the animal leaving the Lt one as control for comparison. Clinical observation of the animals in using their fat injected joints was recorded over the 12 weeks of the experiment. histological examinations of the fat injected and the control joints were done at the end of the experiment. **Results:** All the animals involved in the study were using their treated joints normally on the day following the injection till the end of the experiment. 12 weeks after fat injection the macroscopic and microscopic examinations of both treated and control femoral and tibial surfaces of articular cartilage of hind knee joints showed no sign of joints pathological changes, however, the chondrocytes of femoral and tibial articular cartilage in treated limbs showed proliferation including deferent mitotic stages. **Conclusion:** the injection of autologous fat micro graft intra- articularly is safe practice with no clinical negative manifestations in relation to the fat injected joints of the experimental animals, the macroscopic and microscopic study of the injected joints did not show any pathological changes but give indications of positive proliferative effect on chondrocytes of cartilage in the treated joint.

[Sabah Moshref, Yasir Jamal, Laila A. Hummdi, Abdullah M Kaki and Amro Al-Hibshi. **Intra-articular Injection of Autologous Fat Micro Graft in Sheep Hind Knee Joints.** *Life Sci J* 2013;10(4):2115-2120]. (ISSN: 1545-1003). <http://www.lifesciencesite.org> 281

**Key words:** Knee joints, Fat micro graft, Sheep, Histology, Articular cartilage.

### 1.Introduction

The normal pain free easy gliding of joints depends on the integrity of cartilaginous articular surface and the lubricating synovial fluids. The degeneration of articular cartilage as part of clinical syndrome of osteoarthritis (OA) is one of the common causes of pain, disability, in middle aged and elderly patients. Several methods used to treat the osteoarthritic joint by restoring the damaged articular cartilage which include debridement of degenerated part deep to subchondrial bone, periosteal and perichondrial grafts, use of growth factor, transplantation of chondrocytes and mesenchymal stem cells (MSC) to stimulate new articular surface formation, but none of these methods restore a durable articular surface [1-5].

We believe that intra-articular injection of Autologous fat micro graft is ideal choice to treat the osteoarthritic joints due to its autotogenicity, lubricating nature and the reparative effect of the contained autologous adipose-derived mesenchymal stem cells.

The aim of this animal experimental study is to determine the safety and effects of intra-articular injection of Autologous fat micro graft into hind knee joints of animal model by observing the animals activity in using their injected joints and by examining any macroscopic or microscopic changes in the articular cartilage of the fat injected joints compared to similar non injected joints.

### 2.Materials and Methods

The current study was performed at King Fahd Research Center over 12 weeks on 6 healthy male farmer husbandry sheep were purchased from sheep market in Jeddah, Saudi Arabia, 9–12 months old, weight about 15-18kg. The animals were maintained in sheep house held at  $22 \pm 2^\circ\text{C}$  with a relative humidity of 35–70%. They had free access to a standard diet and tap water. The animals care and all surgical procedures were achieved under the rule of the Animal Welfare Act 1999.

In preparation for the possible use of autologous fat micro graft in the human joints suffering from osteoarthritis (OA) with pain and limitation of joint

movement, the experiment of intra-articular fat micro graft injection was performed on the 6 sheep at king Fahd Research Center animals lab. The animals were sedated with Butorphanol (Stadol®) 5 mg/ Kg and Ketamine (Ketalar®) 2 mg/Kg intramuscular. Under complete sterile technique the surgical site area (fat tail) was prepared, for fat graft harvesting by injecting 20-30 ml of the standard tumescent solution in to the surgical site. Fat harvesting was obtained using ten-holes, Oliveira blunt cannula with 1 mm tip attached to a 10-ml Luer-Lok syringe. 20 ml of fat was collected then it was left for 30 min to settle and separate into various layers. Impurities were removed and the middle layer was kept for intra-articular injection. 7-10 ml of fat micro graft was injected with blunt cannula attached to a 3-ml Luer-Lok syringe capacity in to the right hind knee joint and leaving the left hind knee as control. The evaluation was based on the clinical effect of this procedure on the animal movement utilizing the injected joint and the macroscopic and microscopic examination of the fat injected joint compared to the control aiming of determining the effects of fat micro graft and the contained Adipose-Derived Mesenchymal Stem Cell on the articular surface and the underlying cartilage.

The sheep were slaughtered at the end of experimental period (12 weeks) and femoral and tibial bones of both hind knee joints were removed for tissue preparation. Bone tissues were fixed in 10% buffered formalin solution and after fixation, the bones were transferred to a fresh 10% EDTA solution and decalcified at 37°C for 6 days until softened. After washing in tap water the specimens are dehydrated, clarifying, embedded in paraffin wax. Sections from 3  $\mu$  to 4  $\mu$  thick stained using a standard hematoxylin and eosin (H&E) stain, then the sections washing, dehydrated, cleared, dried and mounted in resinous media [6]. The Count of chondrocytes were taken on the random ten microscopic fields in each H & E stained section of control and treated specimens using the 40X, 100X microscopic lens [7]. The average and standard deviation were calculated using the methods of statistical analysis student's t-test program by Windows SPSS 21.0 for statistical analysis of the data.

### 3. Results

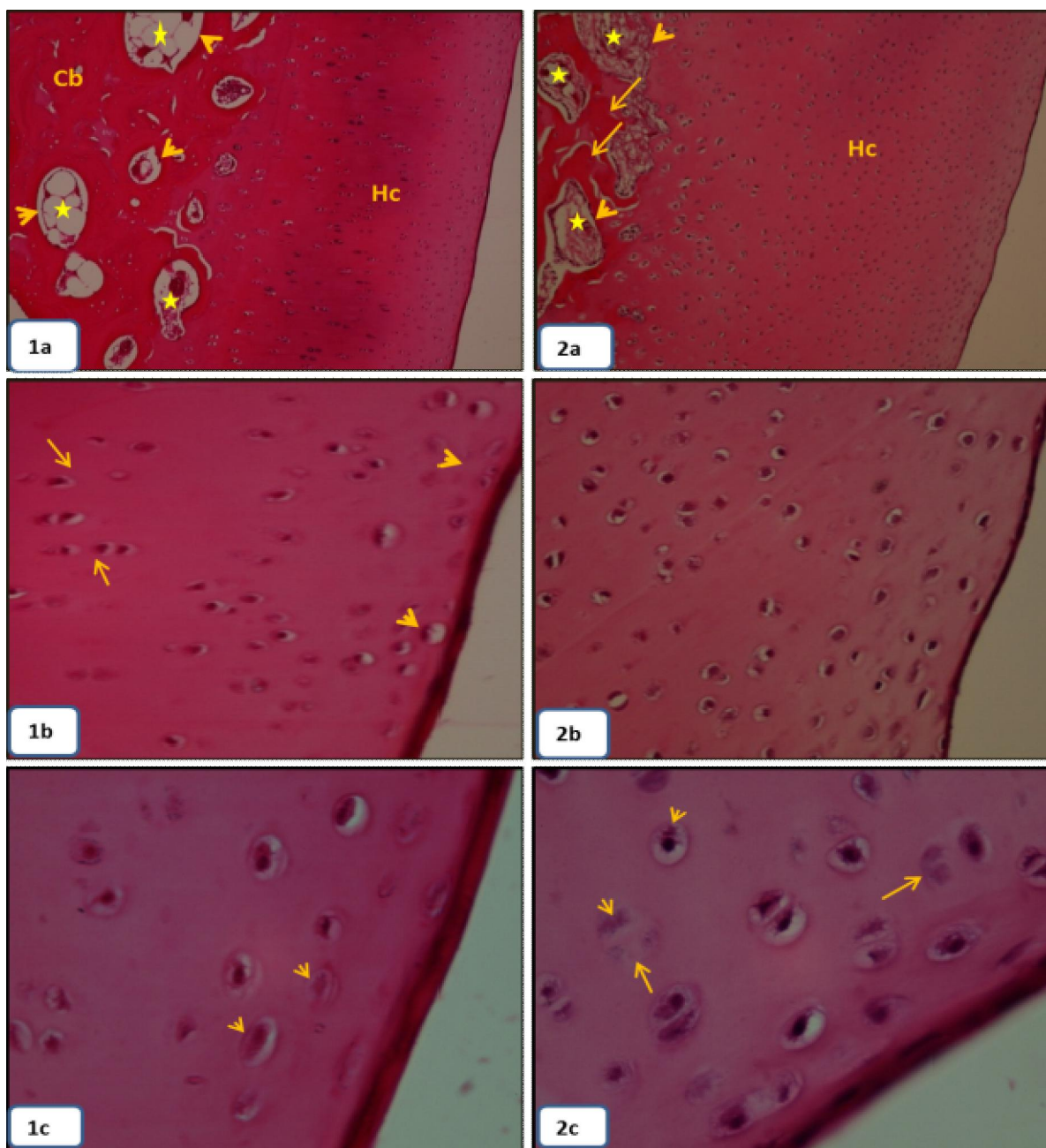
On Clinical observation animals were walking and running normally on the fat injected joints from the day followed the injection till the end of the experiment. The macroscopic and microscopic

examinations of both treated and control femoral and tibial surface of articular cartilage of hind knee joints showed no sign of joints pathological changes in any joint (Figures 1,2,3,4a-c).

The present findings revealed the basic structure of that the control and treated sheep articular surface of femoral and tibial diarthrosis corresponds with previously mentioned in other mammals and human [8-10], which are covered by hyaline cartilage lacks a perichondrium (Figures 1a;2a;3a;4a), superficially placed flattened chondrocytes, which are not organized in groups. Deeply located globular chondrocytes arranged in vertical rows (Figures 1b,c;2b,c;3b,c;4b,c). Likewise, two types of bone are identified in femoral and tibial diarthrosis, a spongy (trabecular) bone covered by a thin layer of compact (dense) bone. The spaces within spongy bone are occupied by the bone marrow and lined by endosteum (Figures 1a;2a;3a;4a). However, in the treated joints the thickness of the articular hyaline cartilage layer was increased and the chondrocytes of femoral and tibial articular cartilage showed proliferation including different mitosis stages (Figures 2b,c;4b,c). Meanwhile, the chondrocytes of femoral cartilage have much higher divide potential than tibial cartilage according to statistical calculations (Table.1).

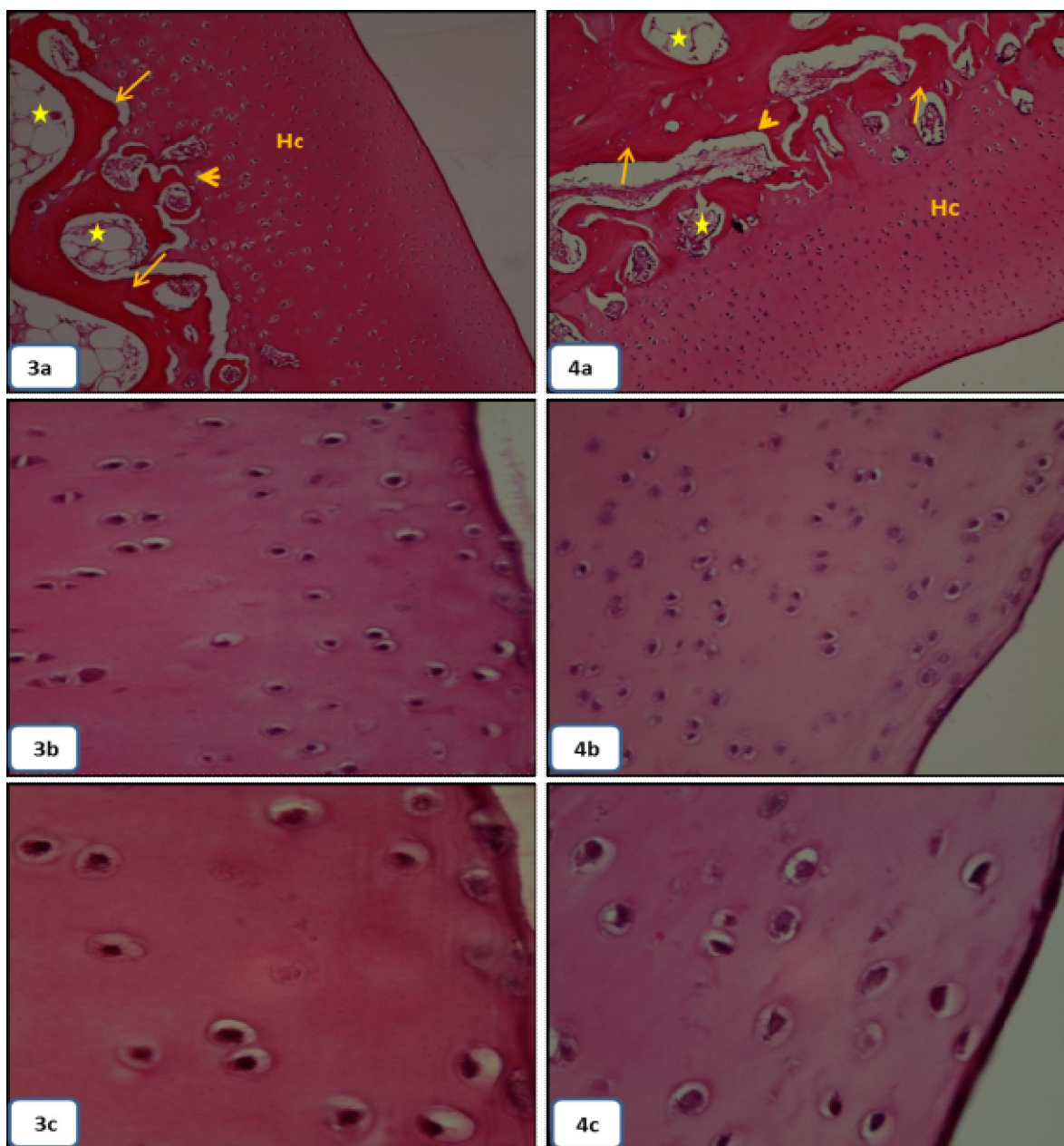
### 4. Discussion

Osteoarthritis is very common condition, It increases with the increase of age leading to arthralgia and limitation of joint movements. several methods of treatment used depending on the degree of severity of the disease ranging from simple analgesics or joint lubricants injection up to joint replacement [5,11-13], but trail of healing of the osteoarthritic joints using the MSC has been reported, where Different cell line technologies are being developed and tried for treatment of joint problems all over the world. Most of these technologies rely on bone marrow or embryonic stem cells that require cell culture and/or manipulation in a laboratory and therefore require scientific studies to prove their long-term safety before they may be granted approval [14-18] but autologous fat micro graft more safer as its stem cells is not manipulated in laboratories, MSC isolated from different tissue sources have the capability of differentiating into different mesenchymal tissue lineages. And tend to migrate to the site of injured tissue to replace damaged cells, increase tissue angiogenesis and promote recovery of injured tissues through growth factor secretion and matrix remodeling [19-23].



**(Figs.1a-c):** Longitudinal sections in femoral diarthrosis of control sheep left hind knee H&E stain; **(a)** normal histological structure of the articular hyaline cartilage (Hc), compact bone(Cb), spongy bone(head arrows)and bone marrow (\*), 100x. **(b,c)**flattened chondrocytes ( head arrows) of the surface layer of hyaline cartilage follows by internal globular chondrocytes arranged in rows (arrows),400x;1000x.

**(Figs.2a-c):** Longitudinal sections in femoral diarthrosis of treated sheep right hind knee H&E stain;**(a)** increasing the thickness of the articular hyaline cartilage (Hc) layer; compact bone(arrows),spongy bone( head arrows)and bone marrow (\*)were observed in normal view, 100x.**(b)** increasing the number of chondrocytes (arrows),400x. **(c)** chondrocytes division, metaphase (head arrows), telophase (arrows) 1000x.



**(Figs.3a-c):** Longitudinal sections in tibialdiarthrosis of control sheep left hind knee H&E stain; **(a)** normal histological structure of the articular hyaline cartilage (Hc), compact bone(arrows), spongy bone(head arrows)and bone marrow (\*), 100x. **(b,c)**chondrocytes of hyaline cartilage, 400x;1000x.

**(Figs.4a-c):**Longitudinal sections in tibialdiarthrosis of treated sheep right hind knee H&E stain; **(a)** increasing the articular hyaline cartilage (Hc) thickness. Note,compact bone (arrows), spongy bone( head arrows) and bone marrow (\*), 100x.**(b,c)** proliferation of chondrocytes,400x ;1000x.

**Table 1. Number of chondrocytes in control and treated articular cartilage of sheep knee joints**

Hind knee joints	Femoral diarthrosis	Tibialdiarthrosis
Control	40.90±0.432	42.72±0.700
	Left joints	
Treated	55.31±0.681**	49.10± 0.585*
	Right joint	

\*: significant at  $P \leq 0.01$ , \*\*: high significant at  $P \leq 0.001$

The idea of using the autologous fat micro graft in treatment of the osteoarthritic joint was proposed by the first author based on the previous experience of the safe and satisfactory results in the use of the autologous fat micro graft in soft tissue augmentation, contouring and rejuvenation, but the injection of fat graft into the joint cavity which was not reported before needed to be tested to determine its safety on the articular surface and to preclude any tissue damage of joint, our animal experiment precluded any clinical functional abnormality or histopathological changes in the fat injected joints, thus our experimental animal study confirm that the autologous fat micro graft is safe as it was not associated detrimental effects on the joint tissues, ideal choice as lubricant and potential healing graft and easy to perform as the small amount of fat needed is easily obtainable, the procedure of harvesting and intra-articular injection is simple and minimally invasive and cheap in comparison to the cost of other artificial lubricants, The procedure harnesses the natural healing power of adipose derived MSC found in fat, as indicated in the positive microscopic findings of the fat injected joints of the experimental animal where the thickness of the articular hyaline cartilage layer was increased and the chondrocytes of femoral and tibial articular cartilages showed proliferation including deferent mitosis stages, other animal experimental studies done in dogs using intra-articular injection of processed autologous adipose-derived mesenchymal stem cells for treatment of osteoarthritis showed Statistically significant improvement in outcome[24,25].

### In conclusions

Autologous fat micro graft is safe healing and soothing joints lubricant with no clinical negative manifestations in the fat injected joints of the experimental animals, the macroscopic and microscopic study of the injected joints did not show any histopathological changes but indicated positive proliferative effects on chondrocytes of cartilage in the treated joint.

### References

- [1] Lawrence, R. C. Helmick, C. G. Arnett, F. C. *et al.*, "Estimates of the prevalence of arthritis and selected musculoskeletal disorders in the United States," *Arthritis and Rheumatism*.(1998); 5(41): 778–799.
- [2] Felson, D. T. Lawrence, R. C. Dieppe, P. A. *et al.*, "Osteoarthritis: new insights. Part 1: the disease and its risk factors," *Annals of Internal Medicine*,(2000),8(133), pp. 635–646.
- [3] Goldring M. B., Goldring S. R. Osteoarthritis. *J. Cell. Physiol.*(2007); 213:626–634. doi: 10.1002/jcp.21258.
- [4] Samuels J., Krasnokutsky S., Abramson S. B. Osteoarthritis: a tale of three tissues. *Bull. NYU Hosp. Jt. Dis.*(2008);66: 244–250.
- [5] Buckwalter JA, Mankin HJ. Articular cartilage: degeneration and osteoarthritis, repair, regeneration, and transplantation. *Instr Course Lect.* (1998);47:487–504.
- [6] Bancroft, J.D. and Gamble, M. Theory and practice of histological techniques. Ahrcourt Health Sciences Company. Churchill. Harcourt publishers Limited. 5th ed..(2002);130–132.
- [7] Hummdi, L. A and Mosule, D.A. Pneumotoxicity and fibrosis in mice induced by a car fuel (gasoline 91) in Saudi Arabia (Histological and Ultra Structure). *African J. Biol. Sci.*,(2011) 7 (2): 85–107. ISSN 1687-4870.
- [8] Armstrong, S.J, Read, R.A, Price, R. Topographical variation within the articular cartilage and subchondral bone of the normal ovine knee joint: a histological approach. *Osteoarthritis Cartilage*.(1995) 3: 25–33.
- [9] Ghadially, F.N, Wedge, J.H, Lalonde, J.M. Experimental methods of repairing injured menisci. *The Journal of Bone and Joint Surgery*.(1986). British Volume 68: 106–10.
- [10] Burger, C, Mueller, M, Wlodarczyk, P, Goost, H. R.H, Tolba, R.H, Rangger, C, Kabir, K. Weber, O. The sheep as a knee osteoarthritis model: early cartilage changes after meniscus injury and repair. *Laboratory Animals*.(2007);41: 420–431
- [11] Pendleton, A. Arden, N. Dougados, M. *et al.*, "EULAR recommendations for the management of knee osteoarthritis: report of a task force of the Standing Committee for International Clinical Studies Including Therapeutic Trials (ESCISIT)," *Annals of the Rheumatic Diseases*.(2000);12(59): 936–944.
- [12] Hernandez-Diaz, S. and Garcia-Rodriguez, L. A. "Epidemiologic assessment of the safety of conventional nonsteroidal anti-inflammatory drugs," *The American Journal of Medicine*.(2001);(110), Supplement 1, no. 3: 20S–27S.
- [13] Hameed, F. Ihm, J. Injectable medications for osteoarthritis. *PM R*.(2012);4(5 Suppl):S75–81.
- [14] Caplan, A.I. Mesenchymal stem cells. *J Orthop Res*.(1991); 9:641–650.
- [15] Caplan AI. Adult mesenchymal stem cells for tissue engineering versus regenerative medicine. *J Cell Physiol*.(2007);213:341–347.

- [16] da Silva Meirelles, L., Chagastelles, P.C, Nardi, N.B. Mesenchymal stem cells reside in virtually all post-natal organs and tissues. *J Cell Sci.*(2006); 119:2204-2213.
- [17] Uccelli A, Pistoia V, Moretta L. Mesenchymal stem cells: a new strategy for immunosuppression? *Trends Immunol.*(2007); 28:219-226.
- [18] Giordano, A, Galderisi, U, Marino, I.R. From the laboratory bench to the patient's bedside: an update on clinical trials with mesenchymal stem cells. *J Cell Physiol.*(2007); 211:27-35.
- [19] Phinney, D.G, Prockop, D.J. Concise review: mesenchymal stem/multipotent stromal cells: the state of transdifferentiation and modes of tissue repair—current views. *Stem Cells.*(2007); 25:2896-2902.
- [20] Chamberlain, G, Fox, J, Ashton, B, *et al.*, Concise review: mesenchymal stem cells: their phenotype, differentiation capacity, immunological features, and potential for homing. *Stem Cells.*(2007); 25:2739-2749.
- [21] Dazz, F, Horwood, N.J. Potential of mesenchymal stem cell therapy. *Curr Opin Oncol.* (2007); 19:650-655. Downloaded from [aes.sagepub.com](http://aes.sagepub.com) by guest on January 27, 2012
- [22] Zuk, P.A, Zhu, M, Mizuno, H, *et al.*, Multilineage cells from human adipose tissue: implications for cell-based therapies. *Tissue Eng.*(2001); 7:211-228.
- [23] Beahm, E.K, Walton, R.L, Patrick, C.W. Progress in adipose tissue construct development. *ClinPlast Sur.*(2003); 30:547-58.
- [24] Black, L.L, Gaynor, J, Adams, C, Dhupa, S, Sams, A.E, Taylor, R, Harman S, Gingerich D.A, Harman, R. Effect of intraarticular injection of autologous adipose-derived mesenchymal stem and regenerative cells on clinical signs of chronic osteoarthritis of the elbow joint in dogs. *Vet Ther.*(2008);9(3):192-200.
- [25] Guercio, A, Di Marco, P, Casella, S, Cannella, V, Russotto, L, Purpari, G, Di Bella, S, Piccione, G. Production of canine mesenchymal stem cells from adipose tissue and their application in dogs with chronic osteoarthritis of the humeroradial joints. *Cell Biol Int.*(2012) 1;36(2):189-94.

11/12/2013