

See discussions, stats, and author profiles for this publication at: <https://www.researchgate.net/publication/309416881>

# Arterial Blood Supply of Liver Segment IV and Its Possible Surgical Consequences

Article in *American Journal of Transplantation* · October 2016

DOI: 10.1111/ajt.14089

CITATIONS

11

READS

238

4 authors, including:



**Thamer Alghamdi**

Albaha University

15 PUBLICATIONS 21 CITATIONS

[SEE PROFILE](#)



**Christoph Justinger**

Klinikum Karlsruhe

66 PUBLICATIONS 710 CITATIONS

[SEE PROFILE](#)



**Thomas Lorf**

Georg-August-Universität Göttingen

169 PUBLICATIONS 3,246 CITATIONS

[SEE PROFILE](#)

Some of the authors of this publication are also working on these related projects:



Cancer screening [View project](#)



Liver transplant [View project](#)

# Arterial Blood Supply of Liver Segment IV and Its Possible Surgical Consequences

T. Alghamdi<sup>1,\*</sup>, C. Viebahn<sup>2</sup>, C. Justinger<sup>1</sup> and T. Lorf<sup>3</sup>

<sup>1</sup>Department of General and Visceral Surgery, Städtisches Klinikum Karlsruhe, Karlsruhe, Germany

<sup>2</sup>Anatomy Center, Georg August University, Göttingen, Germany

<sup>3</sup>Department of General, Visceral and Pediatric Surgery, Universitätsmedizin Göttingen, Göttingen, Germany

\*Corresponding author: Thamer Alghamdi, thamerhg@hotmail.com

Ethic commission approval number: 06/12/13 An.

*This is an open access article under the terms of the Creative Commons Attribution-NonCommercial-NoDerivs License, which permits use and distribution in any medium, provided the original work is properly cited, the use is non-commercial and no modifications or adaptations are made.*

**The risk of ischemia of segment IV after split liver resection is high. This anatomical study was done to identify the arterial blood supply and the intrahepatic distribution of liver segment IV. The anatomy of segment IV was studied in 29 livers from adult cadavers. To identify the arterial blood supply of segment IV, water and ink were injected into the various branches of the hepatic artery and the outflow through segment IV and discoloration of the liver parenchyma were observed. In 23 of the 29 livers (79.3%), the arterial perfusion of segment IV was separated by a line drawn from the left side of the inferior vena cava at the top of and lateral to the falciform ligament to the medial point of the gallbladder bed. The area lateral to this line was supplied mainly by the right hepatic artery, and the area medial to it was supplied mainly by the left hepatic artery. In addition to the classification system of Couinaud, we describe here a new division of liver segment IV based on arterial blood supply. These anatomical findings may be useful in defining the resection line for split liver to prevent necrosis of segment IV.**

**Abbreviations:** ALPPS, associating liver partition and portal vein ligation for staged hepatectomy; IVC, inferior vena cava; LHA, left hepatic artery; MHA, middle hepatic artery; PHA, proper hepatic artery; RHA, right hepatic artery; SIV, segment IV of the liver

Received 21 July 2016, revised 21 September 2016 and accepted for publication 09 October 2016

## Introduction

The Couinaud and Bismuth anatomical classification of the liver is accepted by liver surgeons and transplant communities of Europe, Asia, and North America as the reference for describing partial organ allografts. For this reason, it should be consulted before conducting studies in search of new insights into liver anatomy (1,2).

The Couinaud classification depends particularly on the main stems of the portal and hepatic veins. The liver is divided into two functional hemilivers by the scissures known as the main portal scissure and Cantlie's line, which is the line that runs anteriorly from the middle of the gallbladder bed posteriorly to the inferior vena cava (3). The umbilical fissure and the falciform ligament divide segments II and III from segment IV in the left hemiliver. The tract of the right hepatic vein divides the right hemiliver into anterior segments (segments V and VIII) and posterior segments (segment VI and VII) (4).

Couinaud's method of dividing the liver into eight autonomous liver segments can be accepted as a good approximation. However, the shapes of these segments, their volumes, and their segmental borders show significant variability, which limits the use of this classification in surgical practice (5).

Segment IV is unlike the other segments belonging to the left liver lobe according to the Couinaud classification and forms the border with the right liver lobe. The arterial supply to segment IV has been a topic of debate, and the risk of ischemia, necrosis, and hepatic artery thrombosis of segment IV after split-liver transplantation or the ALPPS (associating liver partition and portal vein ligation for staged hepatectomy) procedure is high (6).

The middle hepatic artery supplies segment IV (7). Identifying this artery and its pattern is important when planning and performing hepatic resection. Accidental damage to this artery can cause a number of complications such as hepatic artery thrombosis, ischemic cholangiopathy, or a decrease in the size of the left hepatic lobe (8).

The arterial blood supply of the posterior aspect of segment IV is not clearly understood. Kobayashi et al (9) reported that arterial blood entered the posterior aspect of segment IV from the right hepatic artery in 8% of the

cases. Miyayama et al (10) described right arterial supply to the posterior aspect of segment IV in 54%. The discrepancy between the two groups may result from the different methods used to analyze the arterial blood flow.

The purpose of our study was to determine the anatomical variations of the hepatic artery, as well as its relationship with the arterial blood supply and intrahepatic distribution to segment IV. All anatomical classifications of liver architecture depend on the main stems of the portal and hepatic veins, but here we concentrate on the arterial blood supply of the liver and define the right and left hepatic lobe depending on the arterial blood supply.

## Materials and Methods

The livers used in this study were recovered from deceased donors donated for education and research to the anatomy center of the Georg August University in Göttingen, Germany. A medical ethics committee reviewed each donation, and an internal review board approved the study.

We studied 29 livers from recently deceased donors without liver cirrhosis or a history of liver surgery.

After the liver was explanted, the porta hepatis and the portal triad were dissected to reveal the anatomical variations of the hepatic arteries, their branches, the origin of the middle hepatic artery, and its insertion into the liver.

The capsule of segment IV was removed along Cantlie's line that separates right and left lobes, and the umbilical fissure and falciform ligament that define the borders between segment IV and segments II and III according to the Couinaud classification (Figure 1A).

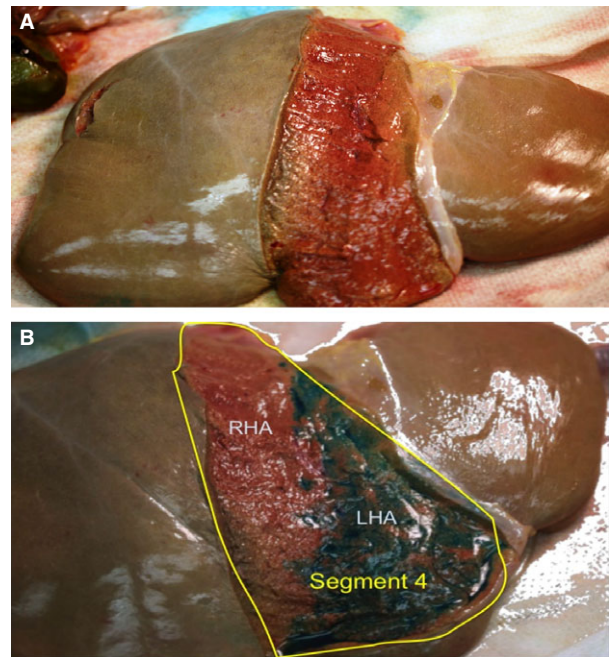
Water was injected into the various branches of the hepatic artery, and the outflow from the superficial part of segment IV was observed. Ink was then injected into the various branches and the discoloration of the liver parenchyma in segment IV and ink outflow were documented and analyzed (Figure 1B).

## Results

### ***The arterial blood supply of segment IV comes from the right and left liver lobes***

A total of 29 livers were dissected. Injecting water and ink into the various arterial branches supplying segment IV revealed a varying distribution of perfusion. In 23 of the 29 livers (79.3%) the distribution was separated by a line drawn from the left side of the inferior vena cava (IVC) cephalad and lateral to the falciform ligament to the medial point of the gallbladder bed.

The blood supply in the area between this line and Cantlie's line came only from the right hepatic artery (RHA) in 19 of the 23 livers (65.6% of all liver samples in the study). In the other four livers, the blood supply was from the RHA and the middle hepatic artery (MHA), which originated from the RHA in all four cases (13.8% of all liver samples in the study).



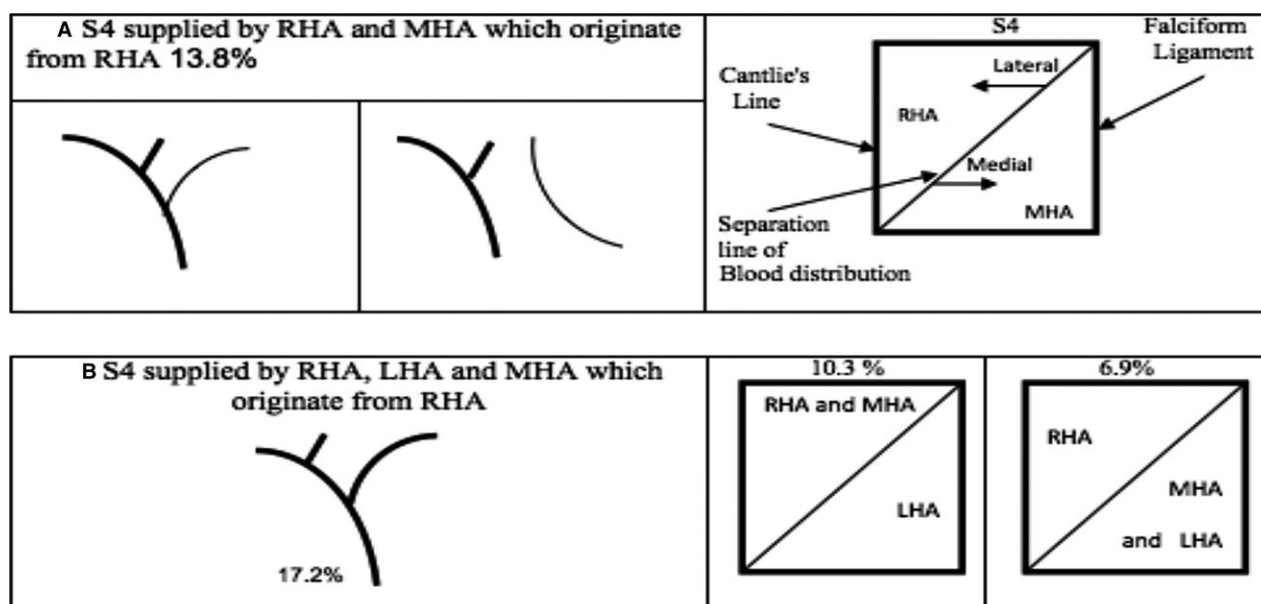
**Figure 1:** (A) The superficial layer of segment IV was removed following Cantlie's line that separates the right from the left lobe (the line runs from the middle of the gallbladder fossa anteriorly to the inferior vena cava posteriorly) and the umbilical fissure and the falciform ligament, which define the borders between segment IV and segments II and III according to the Couinaud classification. (B) Demarcation line after the injection of the ink in the left hepatic artery, which divides segment IV according to the blood supply.

The anatomical variations of the hepatic artery and the intrahepatic blood distribution patterns were so numerous that they could not be categorized in a single format. We therefore divided the specimens on the basis of the source of the arterial blood supply and the intrahepatic blood distribution in liver segment IV.

The blood supply of segment IV arising from the RHA, MHA, and left hepatic artery (LHA) in different patterns of distribution and perfusion were as follows.

In four livers (13.8%), arterial blood for segment IV came from the RHA and the MHA, where MHA was a branch of the RHA. Perfusion lateral to this line came from the RHA and medial to this line from its branch, the MHA. Note that in one liver of this group, the LHA arose from the left gastric artery (Figure 2A).

In a second group of five livers (17.2%), arterial blood was supplied from the RHA, MHA, and LHA, where the MHA was a branch of the RHA (Figure 2B). In 10.3% of this group, perfusion lateral to the described line came from the RHA and its branch the MHA, while the perfusion medial to it came from the LHA. In another 6.9% of



**Figure 2:** (A) and (B) represent two groups with the same extrahepatic variation that the MHA originates from the RHA, and all of them have the demarcation line but different intrahepatic distribution. (A) Perfusion lateral to the demarcation line came from the RHA and medial to this line from its branch, the MHA (LHA was not supplying segment IV in this group). Note that in one liver of this group, the LHA arose from the left gastric artery (LGA). (B) Arterial blood was supplied from the RHA, MHA, and LHA. In 10.3% of this group, perfusion lateral to the described line came from the RHA and its branch the MHA, while the perfusion medial to it came from the LHA. In another 6.9% of the same group, perfusion lateral to the described line came only from the RHA and perfusion medial to it came from the LHA and the MHA. LHA, left hepatic artery; MHA, middle hepatic artery; RHA, right hepatic artery.

the same group, perfusion lateral to the described line came only from the RHA and perfusion medial to it came from the LHA and the MHA, which arose from the RHA.

In a third group of eight livers (27.6%), arterial blood came from the RHA and the MHA, where the MHA was a branch of the LHA. Perfusion lateral to the described line came from the RHA and medial to it came from the MHA, which arose from the LHA (Figure 3A).

In one liver (3.4%), the blood supply came from the RHA, MHA, and LHA where the MHA arose from the LHA (Figure 3B). Perfusion lateral to the described line came from the RHA and medial to it came from the LHA and its branch MHA.

In eight livers (27.6%), there was no MHA and the blood supply to segment IV came from the RHA and LHA (Figure 4). In six of the nine livers, perfusion and distribution were separated by the described line, and the area lateral to it was supplied by the RHA and medial to it by the LHA.

One liver (3.4%) was supplied by the RHA and the MHA. The MHA was doubled here: one arm arising from the RHA and the other from the LHA (Figure 5). Perfusion here was also separated by the described line, and the area lateral to it was supplied by the RHA and its branch MHA, while the area medial to it was supplied

by the left MHA, which arose from the left hepatic artery.

The LHA originated from the left gastric artery in two livers (6.9%) and supplied segment IV in both cases.

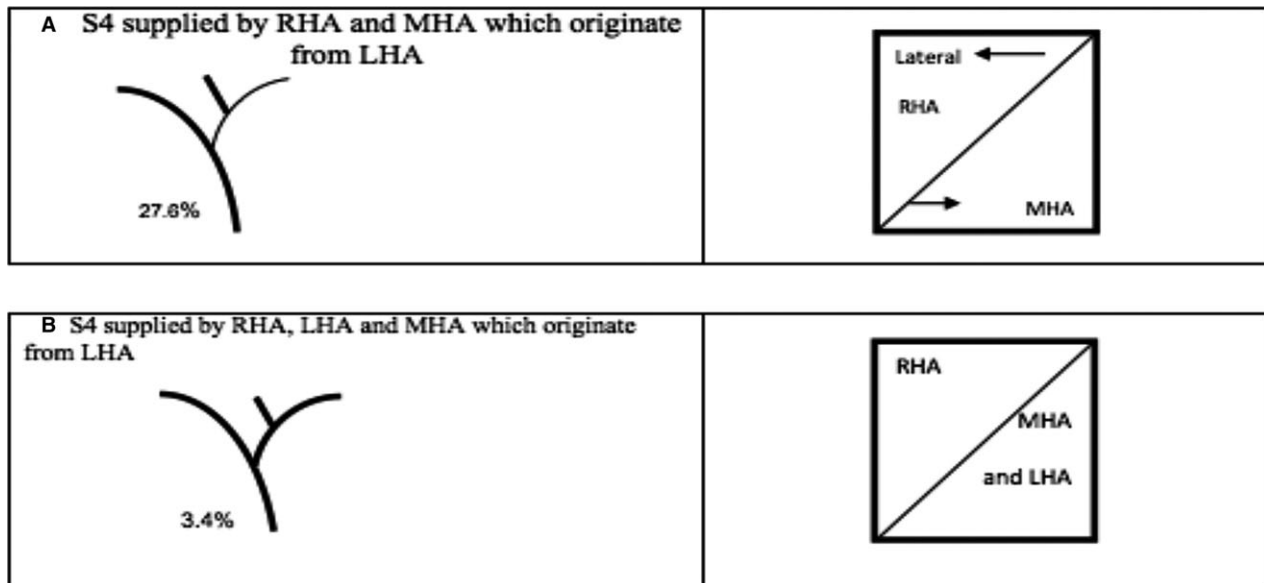
#### **Origin of the MHA, and its perfusion and distribution in segment IV**

The MHA arose from the RHA in nine livers and from the LHA in a further nine instances, giving a frequency of 31% for each occurrence. The MHA originated from the proper hepatic artery (PHA) in one instance (3.4%), but was absent in nine livers (31%). The MHA was doubled in one instance: one arm arising from the RHA and the other from the LHA.


#### **Other forms of perfusion and distribution in segment IV**

In 6 of the 29 livers, the results of the water and ink perfusion were not as described above. In one case, the water and ink perfusion to segment IV came only from the MHA and in this instance, the MHA arose directly from the PHA (Figure 6A).

In four of the six livers (13.8%) the distribution was separated by a line drawn from the IVC at cephalad point and lateral to the falciform ligament to a point equidistant from the gallbladder bed and the round ligament at the



**Figure 3:** (A) and (B) represent two groups with the same extrahepatic variation that the MHAs originate from the LHAs, and all of them have the demarcation line but different intrahepatic distribution. (A) Perfusion lateral to the described line came from the RHA and medial to it came from the MHA (LHA was not supplying segment IV in this group). (B) Perfusion lateral to the described line came from the RHA and medial to it came from the LHA and its branch MHA. LHA, left hepatic artery; MHA, middle hepatic artery; RHA, right hepatic artery.



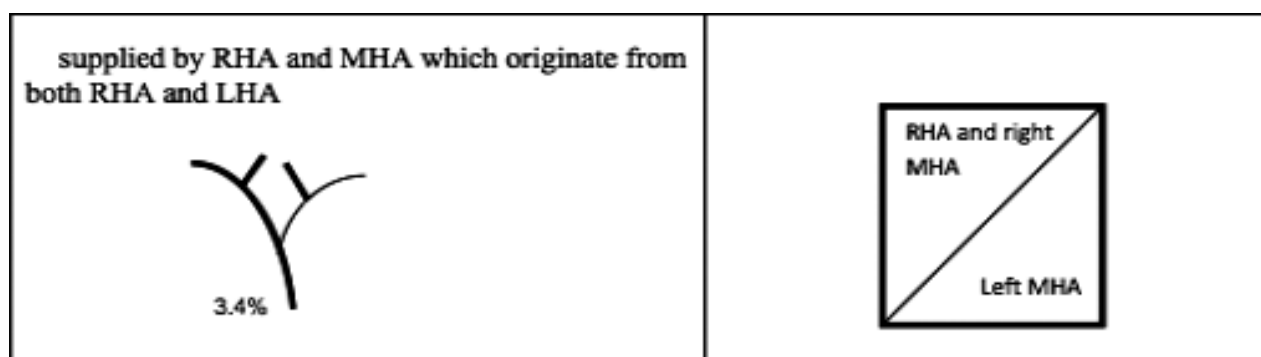
**Figure 4:** There was no MHA and the blood supply to segment IV came from the RHA and LHA; the area lateral to the described line was supplied by the RHA and medial to it by the LHA. LHA, left hepatic artery; MHA, middle hepatic artery; RHA, right hepatic artery.

anteroinferior edge of the liver (Figure 6B). Blood distribution lateral to this line was only from the RHA in all four livers, while distribution medial to it was only from the MHA in two livers and only from the LHA in the other two.

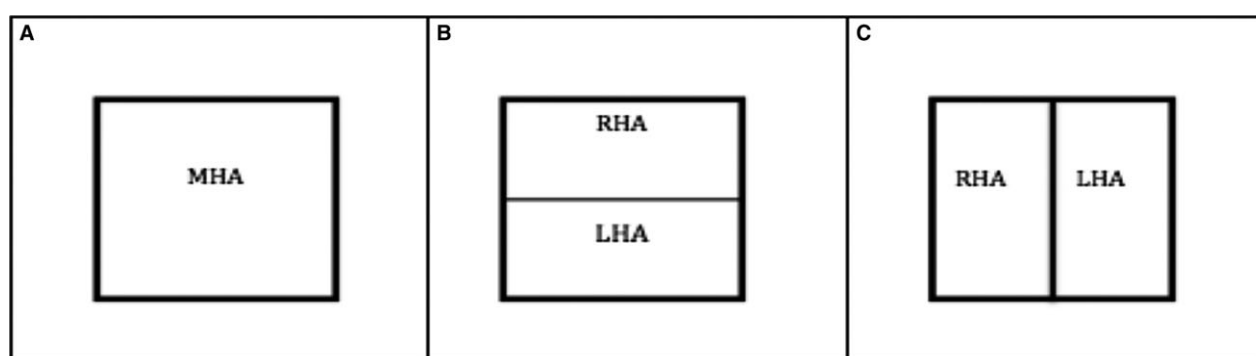
In one liver the distribution of water and ink was divided horizontally into a caudal and cranial part, where the cranial part received perfusion from the RHA and the caudal part received it from the LHA, with the LHA arising from the left gastric artery and there was no MHA (Figure 6C).

## Discussion

Liver surgery depends on the anatomical liver segment classification. There are two different classification systems of hepatic segmentation: that described by Couinaud and the other by Healey and Schroy (1,11). In both systems, the midplane of the liver is defined by Cantlie's line. This line runs anteriorly from the middle of the gallbladder bed to the inferior vena cava posteriorly. The midplane divides the liver into the right and left hemiliver (Couinaud) or the right and left lobe (Healey and Schroy).



**Figure 5: The MHA was doubled here: one arm arising from the RHA and the other from the LHA.** Perfusion here was also separated by the described line, and the area lateral to it was supplied by the RHA and its branch MHA, while the area medial to it was supplied by the left MHA, which arose from the left hepatic artery. LHA, left hepatic artery; MHA, middle hepatic artery; RHA, right hepatic artery.



**Figure 6:** (A) Segment IV was completely receiving its arterial perfusion from the MHA. (B) The distribution was separated by a line drawn from the IVC at the top point to a point equidistant from the gallbladder bed and the round ligament at the anteroinferior edge of the liver. (C) The distribution of water and ink was divided horizontally into a caudal and cranial part, where the cranial part received the water and ink from the RHA and the caudal part received it from the LHA. IVC, inferior vena cava; LHA, left hepatic artery; MHA, middle hepatic artery; RHA, right hepatic artery.

Both of the above classifications use the portal vein and hepatic vein branches to define the right and left lobe. In both classifications, segment IV is part of the left hemiliver. The blood supply of segment IV not only from the portal vein but also from the hepatic arteries is unlike that of the other segments in the segmental liver anatomy and has been a topic of debate (6).

Earlier studies described a different pattern of the origin of the MHA, which supplies segment IV. Healey and Schroy (1953) and Michels (1966) reported that the MHA originated in about equal proportions from the RHA and the LHA (7,12). In our study, the MHA originated from the RHA and the LHA with the same frequency of 31%, while in one case (3.4%) it branched off from the PHA. Numerous other studies reported that the MHA originates from the LHA more often than from the RHA. Suzuki (13) reported that the MHA was a branch of the LHA in 54% of the cases and of the RHA in 34%. In 8%

of the cases it arose at the bifurcation of the PHA and in 4% the MHA was a direct branch of the common hepatic artery. In 2000, Onishi et al reported that the middle hepatic artery branched from the LHA in 61.5%, from the RHA in 27.5%, from the bifurcation of the PHA in 5.5%, and from both the LHA and the RHA in 5.5% of all cases (14). Azoulay et al reported in 2000 that in most cases the MHA originated from the left hepatic artery but could also originate from the RHA, especially in the presence of a replaced LHA (15). In contrast, Jin et al reported in 2008 that the arterial supply to segment IV was mainly via a branch of the RHA or the PHA (16).

In our study, we observed that regardless of the origin of the MHA, the distribution of the ink in the liver parenchyma showed that the blood supply to segment IV was not only from the MHA, but also mainly from the RHA and the LHA. The blood supply lateral to the described line that extends from the left side of the IVC cephalad



and lateral to the falciform ligament to the medial point of the gallbladder bed came from the RHA, and the blood supply medial to this line arose in most cases from the LHA or the MHA originating from the LHA. According to our data, a large area of segment IV is supplied arterially more by the RHA than by the LHA. This finding might influence both oncologic liver surgery and transplant surgery.

Split-liver for transplanting into two larger recipients from one adult deceased donor or liver parenchyma is obtained by transecting at the falciform ligament to create a Couinaud segment II/III graft (left lateral segment graft [LLS]) and a Couinaud segment I, IV–VIII (right trisegment graft [RTS]) (17–20). Yersiz et al described their experience in 100 split-liver transplantations (21). It was noticed that postoperative vascular necrosis and biliary complication occurred more often following a RTS that had a 10% higher incidence of biliary complications and a 7% higher incidence of vascular complications than the left lateral graft. Maggi et al (22) found signs of segment IV hypoperfusion on a computerized tomographic scan after trisegment transplantation (right liver lobe plus segment IV).

According to our findings, creating a right lobe graft that includes all of segment IV means that the area medial to the above-described line will not receive arterial blood since this comes mainly from the LHA. Consequently, the arterial blood supply to the bile ducts in this area will decrease, leading to necrosis of the bile ducts or bile leakage. This might be the reason for the described complications of the trisegment graft in which the parenchyma is transected at the falciform ligament, which can cause hypoperfusion.

The Paris technique of parenchymal transection described by Azoulay and Castaing is performed along the middle of segment IV. Despite leaving on both grafts a slice of theoretically devascularized tissue during the splitting process, they have never experienced any necrosis of the cut surfaces. The line of transection is drawn from the left side of the IVC at the cephalad point, to a point equidistant from the gallbladder bed and the round ligament at the anterior–inferior limit of the liver retaining the middle hepatic vein with the left graft. The two grafts could be used for two adult recipients (23).

The afore-described procedure supports our definition of the demarcation line, which runs in the middle of segment IV. Using our line for parenchymal transection will increase the volume of a left graft and could be transplanted to an adult recipient.

Preservation of biliary vascularization, physiologic arterial perfusion of all segments, and anatomical resection line during transection are some the major technical aspects

with impact on adequate function of the split liver graft (23). Depending on our finding, the LLS graft will not be affected as it receives its arterial blood supply from the LHA but the RTS will be affected, as a part of segment IV that receives its arterial blood from the LHA will not receive enough oxygenated blood after the parenchyma transection at the falciform ligament.

Besides the described advantages in transplant surgery, our findings might influence oncologic liver surgery. When performing the ALPPS procedure (24) in patients with marginally resectable liver metastases, nearly all groups described high rates of biliary leakage and necrosis of segment IV (25).

According to our findings, parts of segment IV are supplied arterially by the RHA and other parts by the LHA. It follows that the parts of segment IV supplied by the LHA will not receive any blood after the first step of the ALPPS procedure. This could explain the high incidence of necrosis and biliary leakage after these operations.

Considering our results regarding the arterial blood supply to segment IV, the division should theoretically be performed from the left side of the IVC at the cephalad point and lateral to the falciform ligament to the medial point of the gallbladder bed to avoid ischemia, necrosis, or cholangiopathy in segment IV.

Taken together and in contrast to the portal venous blood supply, we describe here the arterial blood supply of segment IV, arising from the right and left hepatic artery with a demarcation line between the areas supplied by the RHA and the LHA, that runs from the left side of the IVC at the top and lateral to the falciform ligament to the medial point of the gallbladder. The anatomical findings may be useful in defining the resection line in the split-liver resection or trisegment transplantation and ALPPS procedure. To avoid ischemia, necrosis, or cholangiopathy in segment IV, the division of the hepatic parenchyma should be based on the anatomy of the arterial blood supply and the intrahepatic blood distribution to segment IV. In view of the intrahepatic blood distribution to segment IV, we recommend that the described line be used as the resection line.

## Acknowledgments

The study was conducted in cooperation with the Anatomy Center in Göttingen (Georg August University).

## Disclosure

The authors of this manuscript have no conflicts of interest to disclose as described by the *American Journal of Transplantation*.

## References

1. Le CC. Foie: Etudes Anatomiques et Chirurgicales. Paris: Masson; 1957.
2. Bismuth H. Surgical anatomy and anatomical surgery of the liver. *World J Surg* 1982; 6: 3–9.
3. Cantlie J. On a new arrangement of the right and left lobes of the liver. *J Anat Physiol* 1897; 32: 4–9.
4. Couinaud C. Surgical anatomy of the liver revisited: Embryology. Paris: Couinaud; 1989, p. 11–24.
5. Fischer L, Cardenas C, Thorn M, et al. Limits of Couinaud's liver segment classification: A quantitative computer-based three-dimensional analysis. *J Comput Assist Tomogr* 2002; 26: 962–967.
6. Holbert BL, Baron RL, Dodd GD. Hepatic infarction caused by arterial insufficiency: Spectrum and evolution of CT findings. *AJR Am J Roentgenol* 1996; 166: 815–820.
7. Michels NA. Newer anatomy of the liver and its variant blood supply and collateral circulation. *Am J Surg* 1966; 112: 337–347.
8. Hiatt JR, Gabbay J, Busutil RW. Surgical anatomy of the hepatic arteries in 1000 cases. *Ann Surg* 1994; 220: 50–52.
9. Kobayashi K, Matsui O, Yoshikawa J, Kadoya M, Kawamori Y, Takashima T. Right hepatic arterial supply to the posterior aspect of segment IV of the liver: Analysis by CT during hepatic arteriography. *Abdom Imaging* 1999; 24: 591–593.
10. Miyayama S, Matsui O, Taki K, et al. Arterial blood supply to the posterior aspect of segment IV of the liver from the caudate branch: Demonstration at CT after iodized oil injection. *Radiology* 2005; 237: 1110–1114.
11. Healey JE, Schroy PC. Anatomy of the biliary ducts within the human liver; analysis of the prevailing pattern of branchings and the major variations of the biliary ducts. *Arch Surg* 1953; 66: 599–616.
12. Healey JE, Schroy PC, Sorensen RJ. The intrahepatic distribution of the hepatic artery in man. *J Int Coll Surg* 1953; 20: 133–148.
13. Suzuki H. Correlation and anomalies of the vascular structure in Glisson's area around the hepatic hilum, from the standpoint of hepatobiliary surgery. *Nihon Geka Hokan* 1982; 51: 713–731.
14. Onishi H, Kawarada Y, Das BC, et al. Surgical anatomy of the medial segment (S4) of the liver with special reference to bile ducts and vessels. *Hepatogastroenterology* 2000; 47: 143–150.
15. Azoulay D, Castaing D, Adam R, Mimoz O, Bismuth H. Transplantation of three adult patients with one cadaveric graft: Wait or innovate. *Liver Transpl Surg* 2000; 6: 239–240.
16. Jin GY, Yu HC, Lim HS, et al. Anatomical variations of the origin of the segment 4 hepatic artery and their clinical implications. *Liver Transpl* 2008; 14: 1180–1184.
17. Sommacale D, Farges O, Ertorre GM, et al. *In situ* split liver transplantation for two adult recipients. *Transplantation* 2000; 69: 1005–1007.
18. Yersiz H, Renz JF, Hisatake G, et al. Technical and logistical considerations of *in situ* split-liver transplantation for two adults: Part I. Creation of left segment II, III, IV and right segment I, V–VIII grafts. *Liver Transpl* 2001; 7: 1077–1080.
19. Yersiz H, Renz JF, Hisatake G, et al. Technical and logistical considerations of *in situ* split-liver transplantation for two adults: Part II. Creation of left segment I–IV and right segment V–VIII grafts. *Liver Transpl* 2002; 8: 78–81.
20. Humar A, Khwaja K, Sielaff TD, Lake JR, Payne WD. Technique of split-liver transplant for two adult recipients. *Liver Transpl* 2002; 8: 725–729.
21. Yersiz H, Renz JF, Farmer DG, Hisatake GM, McDiarmid SV, Busutil RW. One hundred *in situ* split-liver transplantations. *Ann Surg* 2003; 238: 496–505.
22. Maggi U, Caccamo L, Reggiani P, et al. Hypoperfusion of segment 4 in right *in situ* split-liver transplantation. *Transplant Proc* 2010; 42: 1240–1243.
23. Rogiers X, Bismuth R, Busutil D, Broering C, Azoulay D. Split Liver Transplantation. Hamburg: Springer; 2002; 46–56.
24. Schnitzbauer AA, Lang SA, Goessmann H, et al. Right portal vein ligation combined with *in situ* splitting induces rapid left lateral liver lobe hypertrophy enabling 2-staged extended right hepatic resection in small-for-size settings. *Ann Surg* 2012; 255: 405–414.
25. Vivarelli M, Vincenzi P, Montalti R, et al. ALPPS procedure for extended liver resections: A single centre experience and a systematic review. *PLoS ONE* 2015; 10: 405–414.